

# EAU Guidelines on Paediatric Urology<sup>1</sup>

H. Riedmiller, P. Androulakakis, D. Beurton, R. Kocvara, E. Gerharz

## Phimosis

### Background

At the end of the first year of life, retraction of the foreskin behind the glandular sulcus is possible in only about 50% of boys; this rises to approximately 89% by the age of 3. The incidence of phimosis is 8% in 6- to 7-year-olds and just 1% in males aged 16–18 years.

### Diagnosis

The diagnosis is made by physical examination.

### Treatment

Therapy of phimosis in children is dependent on parents' preferences and can be plastic or radical circumcision after completion of the second year of life. In case of complicating findings, such as recurrent urinary tract infections (UTIs) or ballooning of the foreskin during micturition, circumcision should be performed without delay regardless of the patient's age. Routine neonatal circumcision to prevent penile carcinoma is not indicated. Contraindications of the operation are acute local infection and congenital anomalies of the penis, particularly hypospadias, as the foreskin may be required for plastic correction.

As a conservative treatment option, a corticoid ointment (0.05–0.1%) can be administered twice a day over a period of 20–30 days. This treatment is not indicated in babies and children still wearing diapers, but may be considered around the third year of life.

Therapy of paraphimosis consists of manual compression of the oedematous tissue with the subsequent attempt to retract the tightened foreskin over the glans penis. If this

manoeuvre fails, a dorsal incision of the constrictive ring is required. Depending on the local findings, a circumcision is carried out immediately or can be performed in a second session.

## Cryptorchidism

### Background

The incidence of maldescensus testis after the first year of life is 1.8–2%. Sliding and pendulous (retractile) testes are particular variations of cryptorchidism.

### Diagnosis

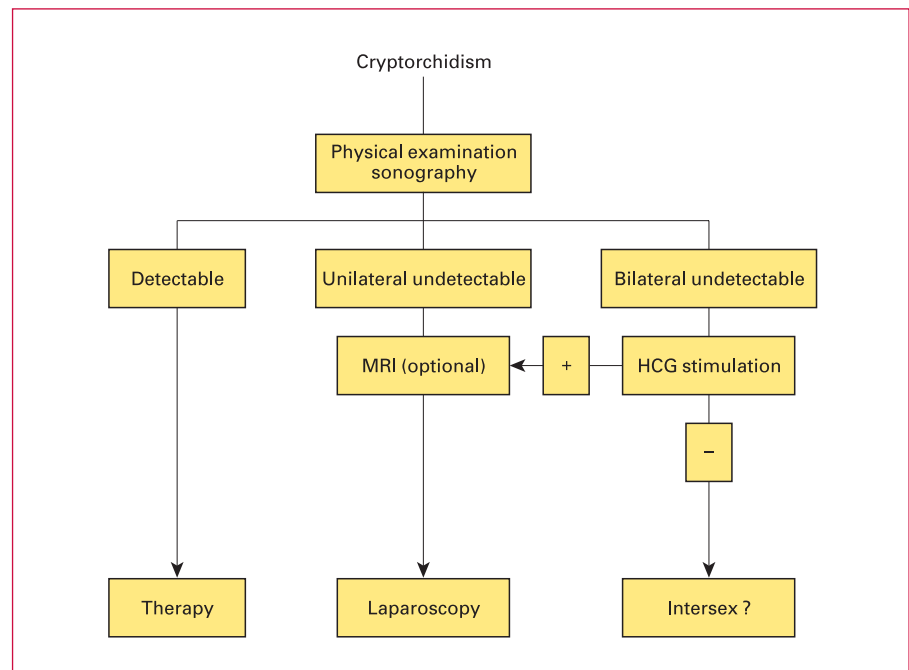
Maldescensus testis is diagnosed by clinical examination. Sonography and magnetic resonance imaging (MRI) may help in localizing the impalpable testis; the accuracy of the latter is 90% for intra-abdominal testis. Once abdominal retention is suspected, laparoscopy has been established as a diagnostic and therapeutic procedure. In this procedure, the testis can be localized in its abdominal position and placed scrotally using the technique appropriate to the anatomical conditions. A human chorionic gonadotrophin (HCG) stimulation test, as evidence of testosterone-producing testis tissue, should precede operative exploration for bilaterally impalpable testes.

### Treatment

The objective of therapy is to achieve an orthotopic scrotal position of the testis before the child's second birthday in order to prevent irreversible damage of spermatogenesis in the affected testis. Hormone therapy (optional) is applied for testis retention only and consists of HCG as an intramuscular injection (9,000–30,000 IU in different protocols) or luteinizing hormone-releasing hormone (LHRH) as nasal

<sup>1</sup>For more extensive information, consult the EAU Guidelines presented at the XVth EAU Annual Congress, Geneva, Switzerland (ISBN 90–806179–3–9).

**Table 1.** Management of cryptorchidism



spray (3×/day 400 µg). Both methods are effective in about 20–30% of cases. Follow-up is important because the benefits may fail after a period of time.

Surgical orchidofuniculolysis and orchidopexy are first-line treatment options; pendulous (retractile) testes are not indicated for surgical repair. If the spermatic funicle is found to be too short, then the Fowler-Stephens technique (ligation and dissection of the spermatic vessels) can be applied. Absolute indications for a primary surgical approach are testis retention after failed hormone therapy or after previous inguinal surgery, testis ectopy and all maldescended testes with associated pathology (hernia and/or open processus vaginalis). Preconditions are intact deferent duct and epididymis vessels. In rare cases, autotransplantation by microsurgical anastomosis of the testis vessels with the epigastric vasculature can be considered (table 1).

## Hypospadias

### Background

Depending on the localization of the external urethral orifice, hypospadias can be subdivided into distal (75%; glandular, coronary, subcoronary), intermediate (13%) and proximal (12%; penoscrotal, scrotal, perineal) forms.

### Diagnosis

A thorough physical examination, urinalysis and usually sonography are performed routinely in all forms of hypospadias. Excretory urogram or voiding cystourethrography (VCUG) are required only in cases of inconclusive findings. Urine trickling and ballooning of the urethra requires exclusion of meatal stenosis by careful inspection.

Diagnostic evaluation also includes assessment of associated anomalies, such as:

- Open processus vaginalis (in 9% of cases)
- Testis in a high position (in 5% of mild forms of hypospadias; in 31% of posterior hypospadias)
- Anomalies of the upper urinary tract (3%).

Severe hypospadias with unilaterally or bilaterally impalpable testis and scrotal transposition require a complete genetic work-up. In case of ambiguous genitalia, retrograde genitography should be performed soon after birth to exclude an adrenogenital syndrome (AGS).

### Treatment

Surgical intervention is recommended for intermediate and more severe forms of hypospadias, and for distal forms with associated pathology (penile curvature, meatal stenosis and phimosis). In simple distal hypospadias, cosmetic correction should be performed only after a thorough discussion of psychological aspects and clarifying the lack of a functional indication.

The therapeutic objective is to correct the penile curvature, to form a neo-urethra and to bring the neo-meatus to the tip of the glans penis, if possible. Preoperative treatment with the local application of testosterone propionate over a period of 4 weeks can be helpful.

For distal forms of hypospadias a range of techniques is available (e.g. Mathieu, MAGPI, King, Duplay, Snodgrass, Onlay). If there is a residual curvature after chordectomy, and if the remaining skin channel of the open urethra is thin and of poor circulation, incision or excision of the urethral plate may be required. In corporeal disproportion, orthoplasty (modification of Nesbit dorsal corporeal plication) must be added. Orthoplasty (Nesbit, modified Nesbit, Schröder-Essed) and closure are to be considered in a two-stage procedure.

The Onlay technique with preservation of the urethral plate and avoidance of circumferential anastomosis is the method of choice, with low complication rates for moderate and severe hypospadias. Prerequisite is an intact and well-vascularized urethral plate, or a satisfactory result after the first session with a straight penis and a well-covered shaft. If the urethral plate is not completely preserved (after excision or division), a tube-onlay flap or an inlay-onlay flap are used. The two-stage procedure may be an option in severe hypospadias. If preputial or penile skin is not available, buccal mucosa, bladder mucosa and free skin grafts can be used.

With regard to complications, meatal narrowing after splint removal can be corrected by careful stretching and the Dittel device. Operative revision is needed in cases of a scarred meatus as slitting and stretching are ineffective in the long term. In urethral stricture, open surgery should be performed after one attempt at internal urethrotomy. With fistulae, revision should not be planned before a lapse of 6 months. To prevent recurrent fistula formation, a dartos flap or a free tunica vaginalis patch may be used. Attention should be paid to adequate subsequent cover with mobilized Scarpa's fasciae.

## Incontinence

### *Background*

Children usually become continent during the daytime by the second year and at night by the fourth year. In cases of persistent wetting, a distinction has to be made between enuresis and urinary incontinence. Particular attention should be paid to anatomic defects of sphincteric muscle and bladder (e.g. complete epispadias, bladder exstrophy, urogenital sinus, ectopic ureter); impaired innervation of

bladder and sphincteric muscle (e.g. myelomeningocele) and functional disturbances of the bladder and sphincteric muscle.

### *Classification*

Enuresis is defined as a normal void occurring at an inappropriate or socially unacceptable time or place. Children with nocturnal enuresis void in bed while asleep and are generally not aroused by the wetting. The condition is monosymptomatic and has a clear familial tendency.

Urinary incontinence is defined as the involuntary loss of urine, objectively demonstrable and constituting a social or hygienic problem. It can be classified according to aetiology as:

- Incontinence associated with anatomic abnormalities of the urinary tract
- Incontinence associated with neurogenic disorder
- Functional incontinence in non-neuropathic bladder sphincter dysfunction (urge syndrome and dysfunctional voiding).

### *Diagnosis*

The basic diagnostic evaluation comprises:

- History (including family and social history)
- Physical, urological and gross neurological examination (urinalysis and culture, specific gravity)
- Sonography (residual urine, bladder wall thickness, upper tracts)
- Frequency-volume chart (after treatment of infection).

If the basic evaluation does not reveal any pathology, an enuresis (uncomplicated, monosymptomatic) can be assumed and no further examinations are required. Further evaluation is required if any pathology is revealed in the basic evaluation and includes:

- Uroflow (if pathological, repeated uroflow and uroflow-EMG study)
- VCUG in case of thickened bladder wall and/or residual urine, in case of pathological, but coordinated micturition
- (Video) urodynamics on suspicion of functional voiding disturbances
- Intravenous urogram (optional if sonography is normal)
- Examination under anaesthesia (urethrocystoscopy, urethral calibration, mainly for UTIs)
- Extended neurological, radiological and psychiatric examinations (including MRI of the spinal cord)
- Radionuclide renal study to assess renal function

**Table 2.** Treatment of urinary incontinence

Condition	Treatment option
<i>Neurogenic disorders</i>	
Detrusor hyperreflexia	Oxybutynin, propiverin or tolterodine
Detrusor sphincter dyssynergia	$\alpha$ -Blockers or polysynaptic inhibitor (baclofenum)
<i>Non-neuropathic bladder-sphincter dysfunction</i>	
Urge syndrome	Bladder rehabilitation; pharmacotherapy (oxybutynin, propiverin, tolterodine); intravesical stimulation and transcutaneous neuromodulation (optional).
Dysfunctional voiding (detrusor sphincter disco-ordination)	Bladder rehabilitation and pharmacotherapy ( $\alpha$ -blockers, polysynaptic inhibitor – baclofenum)
Lazy bladder syndrome	Counselling about regular voiding; clean intermittent catheterization; treatment of constipation; and intravesical stimulation
Hinman syndrome	Treated according to urodynamic examination, counselling about regular voiding, usually clean intermittent catheterization if emptying not complete

### Treatment

*Nocturnal Enuresis (Monosymptomatic).* Therapy is started when the condition becomes distressing and the child becomes motivated to be dry, usually after the age of 5–6 years. Behavioural therapy including motivation, counselling about regular voiding and drinking habits, classical conditioning with alarm-clock, appropriate handling of constipation, is the first option. Complete dryness in 70% and considerable improvement in 12% of cases can be achieved by treatment with 10–40  $\mu$ g DDAVP (desmopressin) nasal spray over a maximum period of 6 months. However, relapse occurs in almost all cases after discontinuation of the medication. Oxybutynin can be helpful in some cases with wetting at the beginning of the night (uninhibited contractions of the bladder).

*Diurnal Enuresis in Children with Attention Disorders.* Treatment options are support and education of parents, appropriate school placement and pharmacotherapy usually handled by child psychiatrists (tricyclic antidepressants).

*Urinary Incontinence.* If recurrent UTIs are present, long-term antibiotic therapy should be started, initially for 6 months. Urinary incontinence is treated according to the aetiology and to urodynamic findings (table 2).

Surgical therapy can be conducted in the case of renal function deterioration, in persistent high filling detrusor pressure and/or urinary incontinence. Options include bladder augmentation, treatment of sphincter weakness and formation of a catheterizable channel.

### Dilatation of the Upper Urinary Tract

#### Background

Hydronephrosis is detectable within the uterus by ultrasound from the 16th week of pregnancy. The commonest causes are ureteropelvic junction (UPJ) stenosis, megaureters, urethral valve syndrome, vesicorenal reflux (VRR) and multicystic renal dysplasia.

#### Diagnosis

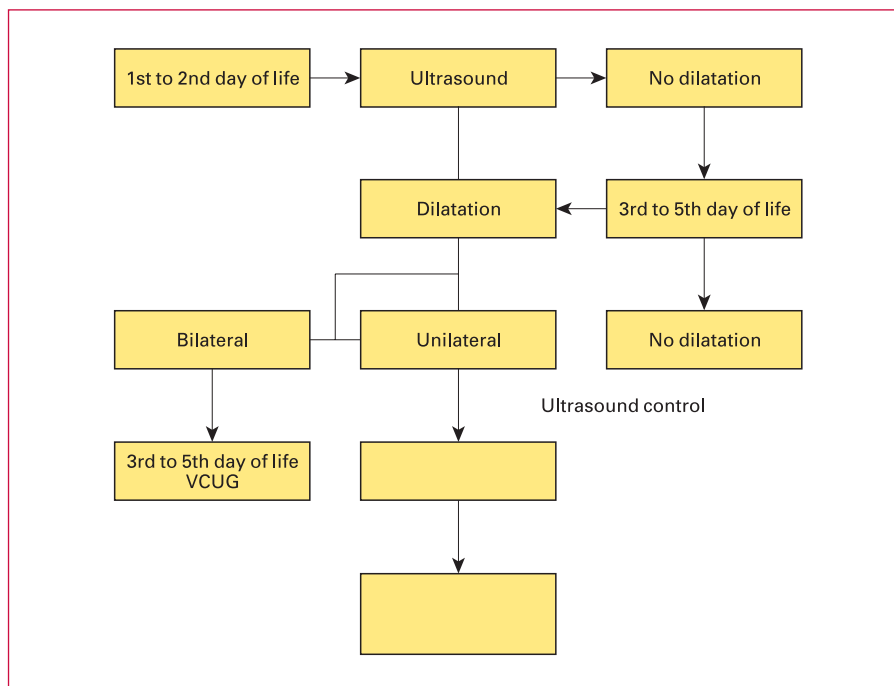
*Ultrasound Examination.* Ectasia, kidney size, thickness of the parenchyma, cortical echo-pattern, width of the ureter, bladder wall thickness and residual urine are assessed during ultrasound examination.

*VCUG.* Preoperatively, reflux should be verified or ruled out by conventional VCUG. Isotope VCUG (lower exposure to radiation) may be used for follow-up.

*Diuresis Renography.*  $Tc^{99m}$ -MAG3 is the radionuclide of choice in diuresis renography. If excretion is impaired, it takes longer for half the maximum activity of the radioisotope to reach the renal pelvis ( $T_{1/2}$ ) after application of furosemide. With rapid absorption of the tracer and prompt washing out effect on diuresis ( $T_{1/2} < 10$  min), obstruction is unlikely.

*Static Renal Scintigraphy.* Renal scintigraphy with dimercaptosuccinic acid is an ideal method for assessment of renal morphology, acute infectious changes, renal scars and functional impairment, for example in multicystic renal

**Table 3.** Follow-up of prenatally diagnosed dilatation of the upper urinary tract



dysplasia and reflux nephropathy. This study should not usually be used within the first 2 months of life.

*Infusion Urogram (IVU).* The IVU is an optional examination method and may be performed preoperatively and in case of inconclusive findings on sonography. The indication for an IVU in the first year of life is problematic.

*Whitaker's Test.* Whitaker's test is carried out as optional antegrade pressure flow study if diagnosis of obstruction is obscure (table 3).

#### Treatment

*UPJ-Stenosis.* Symptomatic UPJ stenosis requires surgical correction, whereas asymptomatic unilateral UPJ stenosis can be subjected to surveillance depending on the grade of obstruction and split renal function.

*Megaureter.* With spontaneous remission rates of up to 85% in primary obstructive megaureters, surgical treatment (ureterocystoneostomy) is required only after recurrent infections under prophylactic antibiotic medication, deterioration of split renal function, concomitant reflux and significant obstruction.

The therapy of the refluxive megaureter is dealt with in the section on VUR (see below).

*Ureterocele.* Orthotopic ureterocele is a rare finding in children, exclusively observed in females and mostly associated with a single kidney system. It seldom requires surgical intervention, mostly due to complications (e.g. lithiasis).

Ectopic ureterocele is dealt with in the section 'Obstructive pathology of renal duplication' (see below).

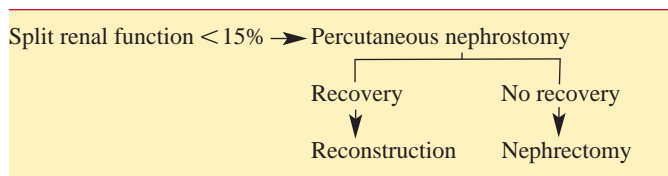
*Retrocaval Ureter.* In this rare condition, the ureter is divided, its course corrected and end-to-end anastomosis is performed.

*Bilateral Hydronephrosis.* Bilateral hydronephrosis and megaureter is very rare in girls and requires an individual approach. In boys, a VCUG should be carried out without delay after sonography. If no pathological findings are discovered, further evaluation follows the 'unilateral hydronephrosis' scheme. In cases of reflux, diagnostic evaluation follows the 'reflux' scheme (see below).

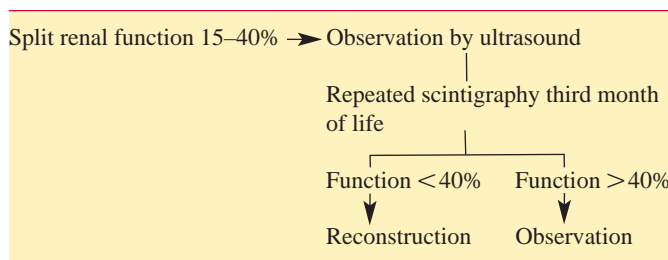
In case of infravesical obstruction with urinary retention, a suprapubic catheter should be inserted immediately and an antegrade VCUG carried out later. If sonographic findings improve and serum creatinine falls below 0.6 mg/dl, endoscopic valve resection should be planned between the first and sixth month of life (depending on the baby's size and weight). If not, supravescical diversion is necessary and delayed reconstruction 6–9 months later should be planned.

*Unilateral Hydronephrosis.* An intervention scheme for prenatally diagnosed unilateral hydronephrosis is shown in tables 4–6.


**Table 4.** Management of prenatally diagnosed hydronephrosis I



**Table 5.** Management of prenatally diagnosed hydronephrosis II



**Table 6.** Management of prenatally diagnosed hydronephrosis III



## Urinary Tract Infection

### Background

UTI can be classified according to four conditions. Asymptomatic bacteriuria is where significant bacteriuria can be documented in consecutive urine samples without any symptoms. In cystitis, the infection is limited to the bladder; irritative symptoms are present, but there are no systemic symptoms or fever. Acute pyelonephritis is a febrile infection of the renal parenchyma. Finally, complicated UTI is due to a urine transport disturbance, malformation or a relevant bladder voiding disturbance.

### Diagnosis

Diagnosis consists of chemical and microbiological urine examination. Sonography is also employed as well as IVU in case of pyelocaliectasis.

### Treatment

*Asymptomatic Bacteriuria.* No treatment is required in children with a normal urinary tract; functional voiding disturbances should be excluded.

*Acute UTI without Pyelonephritis.* Trimethoprim/sulfamethoxazole, trimethoprim (mono-), oral cephalosporins or amoxicillin (third choice) is given for 3–5 days.

*Pyelonephritis.* Intravenous antibiotic therapy with a broad-spectrum penicillin or cephalosporin is started immediately. In case of non-sensitive bacteria, a reserve antibiotic agent is chosen. In newborns, treatment should last for 14–21 days, followed by oral therapy for 7–14 days.

*Cystitis.* Antibiotics are indicated for recurrent cystitis with or without voiding disturbances.

*Complicated UTI.* Efficient management of complicated UTIs requires appropriate treatment of the underlying condition (e.g. impaired urinary drainage).

*Antibiotic Prophylaxis.* Nitrofurantoin and trimethoprim are currently considered as first-line treatment; alternatives are amoxicillin or cephalosporines.

## Reflux

### Background

VUR or VRR are defined as non-physiological back-flow of urine from the urinary bladder into the ureter or the renal pelvis. The worst consequence of both primary and secondary VRR is the development of progressive renal failure secondary to recurrent pyelonephritic episodes and subsequent loss of renal parenchyma. Secondary reflux is due to an anatomically or functionally obstructive or inflammatory illness of the bladder; another cause is direct damage to an orifice.

Reflux can be graded according to increasing severity into grades I–V. The position of the ureteral orifice should be categorized as A (trigonal), B, C or D (markedly lateral).

### Diagnosis

All patients awaiting clarification of a reflux should receive a basic diagnostic work-up, comprising laboratory tests (kidney function), urinalysis and urine cultures, together with a detailed medical history and physical examination. VCUG is the diagnostic tool of choice. Sonography and uroflowmetry are optional tests. Endoscopic examination is helpful in case of planned operative treatment.

In secondary reflux, diagnosis and treatment of the underlying disease are essential.

**Table 7.** Therapy of vesicorenal reflux I

1 year		Conservative
1–5 year(s)	Grades I–III	Conservative
	Grades IV–V	Surgery
>5 years	Boys	Indications for surgery are rare
	Girls	Surgery (due to higher rate of infections, esp. during pregnancy)

**Table 8.** Therapy of vesicorenal reflux II

Recurrent febrile infections despite antibiotic prophylaxis	}	Surgery (not before the age of 6 months)
Additional malformation (double kidney, Hutch diverticulum, ectopic ureter)		

### Treatment

Therapeutic options consist of conservative medical treatment and endoscopic or open surgical procedures. The choice is oriented towards the age of the patient, the grade of reflux, the position or configuration of the ureteral orifices and the clinical course (table 7).

Conservative treatment consists of an ample supply of liquid, regular complete voiding, good hygiene and low dosage, prophylactic long-term antibiotics (table 8).

Currently, experience with endoscopic treatment as an operative option is limited. Various open surgical techniques for reflux correction have been described (e.g. Lich-Gregoir, Politano-Leadbetter, Cohen, Psoas-Hitch), the principle being to lengthen the intramural part of the ureter by submucosal embedding of the ureter. A high success rate of over 95% with only a small rate of complications is shared by all surgical procedures.

## Paediatric Nephrolithiasis

### Background

Stone disease in children is uncommon and is often associated with metabolic disorders, chronic infections and/or morphologic anomalies of the urinary tract. Treatment of paediatric nephrolithiasis must therefore comprise of a strategy to clear the actual stone burden reliably, diagnose and, ideally, eliminate the underlying pathology. Effective measures should be taken to prevent recurrent disease.

### Diagnosis

Children are considered to be high-risk patients and need a full metabolic work-up. The patient's history is particularly important as many metabolic disorders are hereditary. The normal values of the excretion rate of lithogenous and inhibitory agents require correction for body weight.

### Treatment

The first-line treatment of paediatric nephrolithiasis in the absence of obstructive uropathy is extracorporeal shock-wave lithotripsy (ESWL). When planning interventional stone therapy in children the necessity of general anaesthesia must be taken into account for percutaneous litholapaxy (PNL), ureterorenoscopy (URS) and, depending on the child's age, for ESWL. For this reason, the treatment option with the highest probability of success in a single or at most two sessions should be chosen. With larger stones, the probability of a single ESWL session for complete clearance decreases. Indications and complications of interventional stone therapy in children are similar to those in adults.

*Conservative Treatment.* Conservative stone treatment of paediatric nephrolithiasis follows the same rules as in adult patients (e.g. medical dissolution of uric acid stones, antibiotic agents for infection stones).

*Metaphylaxis of Paediatric Nephrolithiasis.* Metaphylaxis of paediatric nephrolithiasis follows the principles detailed in the AWMF guidelines. Dosage of metaphylactic drugs, however, requires appropriate adaptation. Only a medical metaphylaxis should be considered in patients with metabolic disease.

## Obstructive Pathology of the Renal Duplication: Ureterocele and Ectopic Ureter

### Background

Ureterocele is a cystic dilatation developed on the intravesical part of the ureter corresponding to the upper pole of a renal duplication. With ectopic ureter in females, the ureteral orifice may be located in the urethra, the vaginal vestibule, the vagina, the uterus and the Fallopian tube (rarely). In males, the ureteral orifice may be located in the posterior urethra above the verumontanum (never below the external sphincter) and in the seminal tract.

### Diagnosis

*Ureterocele.* Prenatal ultrasound may reveal voluminous obstructive ureteroceles, while at birth, a prolapsed and sometimes strangulated ureterocele in front of the urethral

orifice can identify the congenital abnormality; in neonate boys, this might cause acute urinary retention. The early symptom of pyelonephritis in either sex or the later symptoms of dysuria, recurrent cystitis and urgency can also aid diagnosis.

A VCUg is mandatory in identifying an ipsilateral or contralateral reflux and to assess the degree of intraurethral prolapse of the ureterocele. When the differential diagnosis between ureterocele and ectopic megaureter is difficult, urethroscopy might reveal the pathology.

**Ectopic Ureter.** Most of the ectopic megaureters are diagnosed primarily by ultrasound. In some cases the following clinical symptoms can lead to diagnosis:

- In neonates: pyuria and acute pyelonephritis
- In older girls: dribbling incontinence with concurrent normal micturition
- In preadolescent males: epididymitis and a palpable seminal vesicle.

Ultrasonography, excretory urography, nuclear studies, VCUg and cystoscopy are the diagnostic tools to assess the function, to detect reflux and to rule out ipsilateral compression of the lower pole and urethral obstruction.

#### Treatment

**Ureterocele.** The management of ureterocele is controversial between endoscopic decompression, partial nephroureterectomy, or complete primary reconstruction. The choice of a therapeutic modality depends on the following criteria: clinical status of the patient (e.g. urosepsis); age; renal function of the upper pole; presence or absence of reflux; obstruction of the ipsilateral ureter, and pathology of the contralateral ureter.

If diagnosed early, in the presence of obstruction of the lower pole ureter or contralateral ureter, or urethral obstruction, an immediate endoscopic incision or puncture is recommended in combination with a prophylactic antibiotic treatment. After 3 months a reevaluation is performed, and secondary surgery performed if necessary. With late diagnosis, heminephroureterectomy is the method of choice for non-functional upper pole and no further pathology. In the presence of significant reflux or obstruction, excision of the ureterocele and reimplantation of the ureter/ureters and heminephroureterectomy according to the function of the upper pole is recommended. For bladder outlet obstruction caused by ureterocele, endoscopic incision might be an optional therapy, with awareness of a secondary surgery in the majority of the patients.

**Ectopic Ureter.** In the majority of cases, the upper pole is dysplastic and requires heminephroureterectomy.

**Table 9.** Classification of intersex states (modified from Allen 1976). Major categories grouped by gonadal histology, with subclassification by aetiology

<i>I. Ovary only = female pseudohermaphrodite → karyotype 46XX</i>	
A. Secondary to endogenous androgens (CAH)	
1. 21-Hydroxylase deficiency	
2. 11 $\beta$ -Hydroxylase deficiency	
3. 3 $\beta$ -ol-Dehydrogenase deficiency	
B. Secondary to maternal androgens (exogenous ingestion – endogenous production)	
<i>II. Testis only = male pseudohermaphrodite → karyotype 46XY</i>	
A. Secondary to inadequate androgen (TST) production	
1. 20 $\alpha$ -Hydroxylase deficiency	
2. 3 $\beta$ -ol-Dehydrogenase deficiency	
3. 17 $\alpha$ -Hydroxylase deficiency	
4. 17,20-Desmolase deficiency	
5. 17-ketosteroid reductase deficiency	
B. Secondary to inadequate conversion of TST to DHTST → 5 $\alpha$ reductase deficiency	
C. Secondary to inadequate androgen (TST/DHTST) utilization (androgen receptor deficiency)	
1. Incomplete	
2. Complete (testicular feminization)	
D. Secondary to deficient AMH → hernia uteri inguinalis	
<i>III. Testis plus ovary = true hermaphrodite → Karyotype 46XY, 46XX, mosaic</i>	
<i>IV. Testis plus streak = mixed gonadal dysgenesis → karyotype most often 45XO/46XY</i>	
<i>V. Streak plus streak = pure gonadal dysgenesis → karyotype 45XO (Turner's syndrome), 46XX, 46XY</i>	
<i>VI. Miscellaneous (? Dysgenetic testes ? teratogenic factors)</i>	
CAH = Congenital adrenal hyperplasia; TST = testosterone; AMH = anti-Müllerian hormone; DHTST = dihydrotestosterone.)	

## Intersex (Abnormal Sexual Differentiation)

### Background

Disorders of sexual differentiation most often manifest themselves by the abnormal appearance of the external genitalia as the baby is born, casting doubt on the baby's gender and a lot of anxiety on his/her family. The classification proposed by Allen in 1976 is shown in table 9.

### Diagnosis

The first step of action is to explain to the parents fully and kindly the situation and delay registering and naming the newborn as long as necessary. A careful family history must be taken and the baby carefully examined. The diag-



**Table 10.** Diagnostic work-up of neonates with ambiguous genitalia

1. Good history (family, maternal, neonatal)
Parental consanguinity
Previous intersex disorders or genital anomalies
Previous neonatal deaths
Primary amenorrhoea or infertility in other family members
Maternal exposure to androgens
Failure to thrive, vomiting, diarrhoea of the neonate
2. Physical examination
Pigmentation of genital and areolar area
Hypospadias or sinus urogenitalis
Size of phallus
Palpable and/or symmetrical gonads
Blood pressure
3. Investigations
Buccal smear
Blood: 17-hydroxyprogesterone, electrolytes, LH, FSH, TST, cortisol, ACTH
Urine: adrenal steroids
Karyotype
Ultrasound
Genitogram
HCG stimulation test
Androgen binding studies
Endoscopy

nostic work-up of neonates with ambiguous genitalia is shown in table 10.

It must be remembered that if one can feel a gonad it is almost certainly a testis and virtually excludes female pseudohermaphrodites (i.e. CAH).

The following rules of thumb can be applied regarding a precise diagnosis:

- Positive buccal smear test and no palpable gonads is CAH or female pseudohermaphrodite due to maternal exposure to androgens. In the case of CAH, immediate medical therapy must be instituted (corticosteroid substitution, electrolyte and BP monitoring).

- Buccal smear test negative and one or two gonads palpable (more often inguinal). If there are Müllerian duct structures, then it concerns gonadal dysgenesis or true hermaphroditism; if there are no Müllerian duct structures, the anomaly concerns a male hermaphrodite due either to abnormal testosterone (TST) biosynthesis, inadequate conversion of TST to dihydrotestosterone ( $5\alpha$ -reductase deficiency) or receptor anomaly (androgen insensitivity syndrome).

The decision for appropriate sex assignment is taken on account of a precise aetiological diagnosis and the function-

al potential of the genitalia. Schematically this practical outline can be applied:

- Female pseudohermaphrodites (i.e. CAH) should be reared as female since genitoplasty can correct virilization, and spontaneous puberty, sexual intercourse and fertility are to be expected.

- Male pseudohermaphrodites with an inadequate phallus should be given androgenotherapy and those with a poor clinical response should be reared as girls. The only exception is  $5\alpha$ -reductase deficiency patients, if recognized, in whom a masculine puberty is expected and may be reared as male.

- True hermaphrodites are preferably reared as girls as they have adequate Müllerian structures, i.e. vagina.

- Mixed gonadal dysgenesis patients with inadequate phallus and intra-abdominal testis are preferably reared as girls. Male sex may, however, be chosen when the phallus has adequate size and cavernosum and the testis is palpable, inguinal or scrotal,

- Pure gonadal dysgenesis patients are reared as girls.

#### *Treatment*

*Genitoplasty.* Masculinizing genitoplasty incorporates the following stages:

(a) Androgenotherapy with TST. Its goal is to restore, if possible, a normal penile size, hence it should be used in the first months of life. Systemic or local TST can be administered.

(b) Excision of Müllerian duct structures: firstly because subsequent urethroplasty may cause urine retention and infection within an existing pseudocolpos, and secondly because casual discovery of a retained Müllerian structure later in life may question the patient's gender.

(c) Urethroplasty with release of chordee and correction of scrotal deformities.

d) Orchidopexy of testes that are to be retained.

Feminizing genitoplasty in CAH should be performed once the patient's general status, blood pressure and electrolyte balance have been stabilized by systemic steroid substitution. This is usually achieved around the second to third month of life. The family should be cautioned, however, that reevaluation of the vaginal opening and possibly revision vaginoplasty may be needed at puberty.

*Indications for the Removal of Gonads.* The gonads of intersex patients should be removed in the following cases:

(a) Inappropriate gonadal type for the sex of rearing, as in male pseudohermaphrodites who are to be reared as girls or true hermaphrodites where discordant gonadal tissue is not needed. This type of surgery should be performed as early as possible in the neonate.

**Table 11.** Urodynamics: Normal values in children

<i>Storage phase</i>	
Maximum cystometric bladder capacity:	Age-dependent (approx. age $\times$ 30)
Residual urine	< 10% of the bladder capacity
First desire to void	Bladder filling > 60% of the maximum bladder capacity
Intravesical pressure	14 cm H <sub>2</sub> O at the beginning, up to 24 cm H <sub>2</sub> O at the end of the filling
Involuntary detrusor contraction	None
Compliance	> 25 ml/cm H <sub>2</sub> O
Electromyography	Stable
<i>Micturition phase (mictiometry)</i>	
Maximum urine flow	Age-dependent
Medium urine flow	Age-dependent
Micturition pressure	< 75 cm H <sub>2</sub> O (age-dependent)
Electromyography	Fluctuations

(b) High risk of malignancy (gonadoblastoma/dysgerminoma). Particularly for patients with mixed gonadal dysgenesis and those with true gonadal dysgenesis and 46XY karyotype. To a lesser extent, for male pseudohermaphrodites with androgen receptor insensitivity and true hermaphrodites with 46XY karyotype. The risk for gonadal tumour is real after puberty, hence this type of surgery can be postponed until that age.

## Urodynamic Investigations

### *Residual Urine*

Residual urine volume can be considered clinically significant when the volume measured on repeated occasions is > 20 ml or over 10% of cystometric bladder capacity.

### *Uroflowmetry*

This involves measurement, either sitting or standing, of voided volume, micturition time, average and maximum urine flow rate; the latter is only valid if the bladder is filled to more than half of its total capacity.

### *Cystometry*

Cystometry measures intravesical and intra-abdominal pressures during storage and voiding phases. If a neuropathic bladder is suspected, provocation with 20 ml of ice water with about 50 ml bladder filling may be carried out. Non-suppressible detrusor contractions are signs of neurogenic disinhibition. The carbachol test allows differentiation between neurogenic and myogenic detrusor contractility. In neurogenic bladder dysfunction, an intravesical pressure rise of > 25 cm H<sub>2</sub>O as overreaction of the bladder

denervation to the cholinergic stimulation after 20–30 min is recorded.

### *Video-Urodynamic Evaluation*

Using contrast media, video-urodynamic evaluation combines fluoroscopic recording of bladder filling and emptying with simultaneous urodynamic examination. The most important indication for video-urodynamic evaluation is abnormal voiding (i.e. differential diagnosis of bladder outlet obstruction versus neuropathic vesicourethral dysfunction).

### *Urethral Pressure Profile (Sphincterometry)*

Static or stress profile of the urethra is used to determine and quantify sphincter insufficiency; however, the method cannot verify subvesical obstruction. Urethral pressure profilometry is indicated in the assessment of stress incontinence (e.g. post-traumatic, sinus urogenitalis, myelomeningocele).

### *Electromyography (EMG) of the External Sphincter*

In normal subjects, there is a gradual increase in EMG activity from the pelvic floor during bladder filling; at the onset of micturition, there is complete absence of activity. The finding of increased EMG activity during voiding, accompanied by simultaneous detrusor pressure and flow changes, is described by the term detrusor-sphincter dyssynergia (in neuropathic bladder/sphincter dysfunction) or detrusor-sphincter discoordination (in neurologically normal children). Because of the many artefacts noted and the inability to distinguish electronic 'noise' from true EMG potentials on the recording, there is no consensus about using the EMG registration (table 11).

## References

In view of the diversity and complexity of the addressed issues on the one hand and the necessity to limit the number of cited articles on the other, an incorporation of the references into the text seems inappropriate.

### Phimosis

- 1 Gerharz EW, Haarmann C: The first cut is the deepest? Medicolegal aspects of male circumcision. *Br J Urol* 2000;86:332–338
- 2 Moses S, Bailey RC, Ronald AR: Male circumcision: Assessment of health benefits and risks. *Sex Transm Infect* 1998;74:368–373.
- 3 Williams N, Kapila L: Complications of circumcision. *Br J Surg* 1993;80:1231–1236.

### Cryptorchidism

- 1 Alaish SM, Stylianos S: Diagnostic laparoscopy. *Curr Opin Pediatr* 1998;10:323–327.
- 2 Canavese F, et al: Cryptorchidism: medical and surgical treatment in the 1st year of life. *Pediatr Surg Int* 1998;14:2–5.
- 3 Nguyen HT, Coakley F, Hricak H: Cryptorchidism: Strategies in detection. *Eur Radiol* 1999;9:336–343.

### Hypospadias

- 1 Asopa HS: Newer concepts in the management of hypospadias and its complications. *Ann R Coll Surg Engl* 1998;80:161–168.
- 2 Baskin LS, et al: Changing concepts of hypospadias curvature lead to more onlay island flap procedures. *J Urol* 1994;151:191–196.
- 3 Borer JG, Retik AB: Current trends in hypospadias repair. *Urol Clin North Am* 1999;26:15–37.
- 4 Riedmiller H: Hypospadias 2000. *Akt Urol* 2000;31:147–148.
- 5 Weidner IS, et al: Risk factors for cryptorchidism and hypospadias. *J Urol* 1999;161:1606–1609.

### Incontinence

- 1 Elder JS: Bladder rehabilitation, the effect of a cognitive training programme on urge incontinence. *J Urol* 1997; 158: 1642.
- 2 Hjalmas K: What's new in nocturnal enuresis? Old concepts and new knowledge; in Kennedy (ed): *European Union of General Practitioners' Reference Book – Clinical Care*, 1998/99.
- 3 Norgaard JP, et al: Standardization and definitions in lower urinary tract dysfunction in children. *International Children's Continence Society. Br J Urol*, 1998;81(suppl 3):1–16.
- 4 Wan J, Greenfield S: Enuresis and common voiding abnormalities. *Pediatr Clin North Am* 1997;44:1117–1131.
- 5 Van Gool JD, et al: Conservative management in children; in Abrams, Khoury, Wein, *Incontinence*. Plymouth, Health Publications, 1999, pp 487–550.

### Dilatation of the Upper Urinary Tract

- 1 Borhan A, Kogan BA, Mandell J: Upper ureteral reconstructive surgery. *Urol Clin North Am* 1999;26:175–181.
- 2 Chevalier RL, Klahr S: Therapeutic approaches in obstructive uropathy. *Semin Nephrol* 1998;18:652–658.
- 3 Dhillon HK: Prenatally diagnosed hydronephrosis: The Great Ormond Street experience. *Br J Urol* 1998;81(suppl 2):39–44.
- 4 King LR: Hydronephrosis. When is obstruction not obstruction? *Urol Clin North Am* 1995;22:31–42.
- 5 Reddy PP, Mandell J: Prenatal diagnosis. Therapeutic implications. *Urol Clin North Am* 1998;25:171–180.

### Urinary Tract Infection

- 1 Downs SM: Technical report: Urinary tract infections in febrile infants and young children. The Urinary Tract Subcommittee of the American Academy of Pediatrics Committee on Quality Improvement. *Pediatrics* 1999;103: E54.
- 2 Rushton HG: Urinary tract infections in children. Epidemiology, evaluation, and management. *Pediatr Clin North Am* 1997;44:1133–1169.
- 3 Smellie JM, Rigden SP: Pitfalls in the investigation of children with urinary tract infection. *Arch Dis Child* 1995;72:251–255.

### Reflux

- 1 Beetz R, et al: Long-term follow-up of children with surgically treated vesicorenal reflux. *Eur Urol* 1989;16:366–371.
- 2 Belman AB: Vesicoureteral reflux. *Pediatr Clin North Am* 1997;44:1171–1190.
- 3 Garin EH, Campos A, Homsy Y: Primary vesicoureteral reflux: Review of current concepts. *Pediatr Nephrol* 1998;12:249–256.
- 4 Shapiro E, Elder JS: The office management of recurrent urinary tract infection and vesicoureteral reflux in children. *Urol Clin North Am* 1998;25:725–734.
- 5 Smellie JM, et al: Childhood reflux and urinary infection: A follow-up of 10–41 years in 226 adults. *Pediatr Nephrol* 1998;12:727–736.
- 6 Wingen AM, et al: Growth and weight gain in children with vesicoureteral reflux receiving medical versus surgical treatment: 10-year results of a prospective, randomized study. *International Reflux Study in Children (European Branch). Acta Paediatr* 1999;88:56–61.

### Paediatric Nephrolithiasis

- 1 Brändle E, Hautmann R: Leitlinie zur Metaphylaxe des Harnsteinleidens: <http://www.rz.uni-duesseldorf.de/www/AWMF/11/urol-026.htm> (Arbeitsgemeinschaft der Wissenschaftlichen Medizinischen Fachgesellschaften).
- 2 Cohen TD, et al: Pediatric urolithiasis: Medical and surgical management. *Urology* 1996; 47:292–303.

- 3 Esen T, Krautschick A, Alken P: Treatment update on pediatric urolithiasis. *World J Urol* 1997;15:195–202.
- 4 Kroovand RL: Pediatric urolithiasis. *Urol Clin North Am* 1997;24:173–184.

### Obstructive Pathology of the Renal

#### Duplication: Ureterocele and Ectopic Ureter

#### Ureterocele

- 1 Husmann D, Strand B, Ewalt D, Clement M, Kramer S, Allen T: Management of ectopic ureterocele associated with renal duplication: A comparison of partial nephrectomy and endoscopic decompression. *J Urol* 1999;162: 1406–1409.
- 2 Montfort G, Ruys JM, Coquet M, Roth K, Louis C, Bocciardi A: Surgical management of duplex ureteroceles. *J Pediatr Surg* 1992;27: 634–638.
- 3 Roy GT, Desai S, Cohen RC: Ureteroceles in children: An ongoing challenge. *Pediatr Surg Int* 1997;12:44–48.

#### Ectopic Ureter

- 1 Smith FZ, et al: Surgery for duplex kidneys with ectopic ureters: Ipsilateral ureteroureterectomy versus polar nephrectomy. *J Urol* 1989;142:532–534.

#### Intersex (Abnormal Sexual Differentiation)

- 1 Allen TD: Disorders of sexual differentiation. *Urology* 1976;7(suppl):1–32.
- 2 Androulakakis PA: *Pediatric Urology*. Athens, Beta Publishing, 1993.
- 3 Reiner WG: Sex assignment in the neonate with intersex or inadequate genitalia. *Arch Pediatr Adolesc Med* 1997;151:1044–1045.
- 4 Whitaker RH, Williams DM: Diagnostic assessment of children with ambiguous genitalia. *Eur Urol Update Series* 1993;2:2–7.

#### Urodynamics

- 1 Hoebeke P, et al: Urodynamics in children: What and how to do it? *Acta Urol Belg* 1998; 66:23–30.
- 2 Nijman RJ: Pitfalls in urodynamic investigations in children. *Acta Urol Belg* 1995;63: 99–103.
- 3 Norgaard JP, et al: Standardization and definitions in lower urinary tract dysfunction in children. *International Children's Continence Society. Br J Urol* 1998;81(suppl 3):1–16.

paediatric urology. 4. eau guidelines. 4. urology. 1. paediatric. 1. eau. 1. Member Articles. Near- and Extended-Edge X-Ray-Absorption Fine-Structure Spectroscopy Using Ultrafast Coherent High-Order Harmonic Supercontinua. Please type a message to the paper's authors to explain your need for the paper. Paper: EAU guidelines on paediatric urology. To: H Riedmiller, P Androulakakis, D Beurton, R Kocvara, E Gerharz, From (Name)