



## REVIEW ARTICLE

# RECENT MANAGEMENT OF HEMORRHOIDS : A PHARMACOLOGICAL & SURGICAL PERSPECTIVE

**Saurabh Gupta<sup>1</sup>, Thakur Gurjeet Singh<sup>1\*</sup>, Suman Baishnab<sup>1</sup>, Nidhi Garg<sup>1</sup>, Kiranjeet Kaur<sup>1</sup> and Saurabh Satija<sup>2</sup>**

<sup>1</sup>Chitkara College of Pharmacy, Chitkara University, Punjab, India

<sup>2</sup>School of Pharmaceutical Sciences, Lovely Professional University, Phagwara, Punjab, India

\*Author for correspondence: E-mail: gurjeet.singh@chitkara.edu.in; gurjeetthakur@gmail.com

### Abstract

Hemorrhoids, likewise called piles, are swollen veins in the anus and lower rectum, like varicose veins. Hemorrhoids are portrayed by the symptomatic broadening and distal dislodging of the ordinary anal cushions. Many components have been claimed to be the occurrences of hemorrhoidal development, including constipation and delayed straining. Hemorrhoid tissues are a system of veins situated in and around the anal trench (the last couple of inches of the rectum). At the point when these veins swell, the patient can have manifestations, for example, pain or a burning sensation, Bleeding amid bowel movement, Protrusion of tissue from the anus, Itching around the anus. Hemorrhoids are a standout amongst the most widely recognized reasons that patients look for consultation from a colon and rectal surgeon. Hemorrhoidal disorder has been recorded through hundreds of years of history. Primitive references are found in the Old Testament and in Egyptian, Babylonian and Greek composed sources. Although there are few treatment options available for the treatment of Hemorrhoids, but there is very less or limited knowledge about the complete treatment options and new treatment that are available for treating Hemorrhoids. This review article on Recent Advances in the Treatment of Hemorrhoids will unfold various options (both existing and novel) available for the management of this disorder. The aim stands to prevent morbidity and mortality if any due to this disorder. The review will also unfold management of hemorrhoids via surgical procedures.

**Keywords:** Hemorrhoids, Piles, Internal Hemorrhoids, External Hemorrhoids, Treatment of Hemorrhoids.

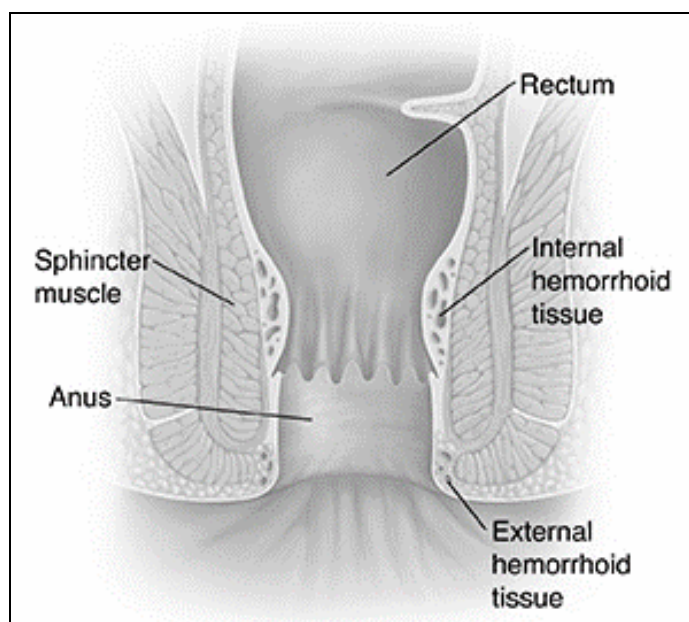
### Introduction

Hemorrhoids, likewise called piles, occurs in the anus and lower rectum due to swelled up veins, like varicose veins (Mayoclinic, 2019). Hemorrhoids are portrayed by the symptomatic broadening and distal dislodging of the ordinary anal cushions (Agrawal and Chopra, 2016). Many components have been claimed to be the occurrences of hemorrhoidal development, including constipation and delayed straining (Agboo, 2011). Hemorrhoid tissues are a system of veins situated in and around the anal trench (the last couple of inches of the rectum). At the point when these veins swell, the patient can have manifestations, for example, Pain or a burning sensation, Bleeding amid bowel movement, Protrusion of tissue from the anus, Itching around the anus (Krames Patient Education, 2010). Hemorrhoids are a standout amongst the most widely recognized reasons that patients look for consultation from a colon and rectal surgeon (Sanchez and Chinn, 2011). Hemorrhoidal disorder has been recorded through hundreds of years of history (Margetis, 2019). Primitive references are found in the Old Testament and in Egyptian, Babylonian and Greek composed sources (Holley, 1946; Senagore, 2002; Ellesmore & Windsor, 2002).

### Internal and Pathophysiological Aspects

Hemorrhoids are ordinary structures of the human body (Mott *et al.*, 2018; Ganz, 2013; Jacobs, 2014). Internal hemorrhoids emerge from the inward hemorrhoidal plexus, while outer hemorrhoids emerge from the outside plexus. The anatomical boundary that isolates the inward from the outside hemorrhoidal plexus is the dentate line (Sandler and Peery, 2019; Mott *et al.*, 2018; Ganz, 2013). The typical inner hemorrhoidal plexus comprises of 3 delicate engorgements, alluded to as anal cushions or "hemorrhoids" (Jorge and Gama, 2011; Hyung, 2014). Consequently, the

expression "internal hemorrhoids" does not imply a condition of disorder whenever seen in its severe strict definition. Be that as it may, in clinical practice the expression "internal hemorrhoids" is utilized to portray exclusively the disorder coming about because of the abnormal amplification of anal cushions, i.e., their change to anal nodules (Ganz, 2013; Jorge and Gama, 2011; Hyung, 2014). More specifically, this definition is restricted to symptomatic hemorrhoidal ailment: i.e., anal cushions are named "hemorrhoids" when they bleed as well as prolapse (Margetis, 2019).



**Fig. 1:** Parts of Anal Canal (Krames Patient Education, 2010)<sup>102</sup>

## Classification of Hemorrhoids

Hemorrhoids can be categorized by their area and level of prolapse. Internal hemorrhoids are situated over the dentate line and secured by columnar epithelium. Whereas, external hemorrhoids, are situated underneath the dentate line and secured with squamous epithelium. Mixed hemorrhoids are known as "interno-external" hemorrhoids and are found both over and underneath the dentate line (Hulme and Bartolo, 2001).

Internal hemorrhoids are additionally graded by Goligher's characterization which relies upon the level of prolapse into: (Salvati, 1999)

Grade I hemorrhoids: Anal cushions bleed without prolapse.

Grade II hemorrhoids: Anal cushions prolapse on stressing however lessen unexpectedly.

Grade III hemorrhoids: Anal cushions prolapse on stressing or effort and require manual reduction.

Grade IV hemorrhoids: The prolapse is unchangeable and stays out constantly.

**Internal Hemorrhoid:** Internal hemorrhoids lie over the dentate line and are secured by columnar cells that have visceral innervations. These drain by means of the center rectal veins into the inside iliac vessels.

**External Hemorrhoid:** External hemorrhoids are situated beneath the dentate line and drain by means of the inferior rectal veins into the pudendal vessels and after that into the inward iliac vein. These vessels are secured by anoderm that is contained of modified squamous epithelium. Subsequently, these tissues contain pain fibers and affect how patients present and are dealt with.

## Pathogenesis

In spite of the fact that hemorrhoidal cushions are ordinary anatomic structures, they are rarely alluded to until issues emerges, and afterward the term hemorrhoid is implied as a pathologic process. The pathogenesis of hemorrhoids isn't totally clear (Kann and Whitlow, 2004). A study stated that there is a relationship among hyper vascularization and the occurrence of hemorrhoidal sickness as they detailed that the terminal parts of the superior hemorrhoidal artery in patients with hemorrhoidal disorder had a fundamentally bigger diameter and more prominent blood flow, just as higher pinnacle velocity and acceleration velocity, when contrasted with those of healthy controls.

In any case, the sliding anal trench lining theory, which is the most acknowledged theory, expressed that hemorrhoidal disorder develops upon endless supply of the supporting tissues of anal cushions prompting their downward displacement. Various conceivable contributing variables prompting relocation of the hemorrhoidal cushions have been proposed, including absence of dietary fiber, delayed stressing, spending more time on the comode, constipation, diarrhea, pregnancy, sedentary life, and a family ancestry. Aside from pregnancy, none of these etiologies are upheld by good evidence (Thomson, 1975; Deutsch *et al.*, 1987; Johannsson *et al.*, 2005).

Ongoing investigations analyzed the job of a few enzymes or arbiters which might be engaged with the degradation of supporting tissues in the anal cushions like

matrix metalloproteinase, which was observed to be over-expressed in hemorrhoids. Since the revelation of increased microvascular density in hemorrhoidal tissue, neovascularization has been proposed as a significant phenomenon in the pathogenesis of hemorrhoidal disease (Kluiber and Wolff, 1994; Yoon *et al.*, 2005).

## Clinical Presentation

Patients habitually whine of bleeding with or without stool excretion, a swelling, mellow distress or irritation. Various presentation may incorporate soilage or mucous release, pruritis, challenges with cleanliness, and a feeling of inadequate evacuation.

Internal hemorrhoids are painless until & unless if they are thrombosed, prolapsed with edema, or strangulated (Smith, 2004). External hemorrhoids result in pain when a thrombosis happens and bleeding if ulceration happens from pressure putrefaction. Skin tags may frame from acute edematous or thrombosed external hemorrhoids (Sanchez and Chinn, 2011).

Manifestations from hemorrhoids are like different disorders and the differential finding ought to incorporate anal crevices, rectal prolapse, abscesses and fistulas, IBD, and neoplasia. The clinical history gives intimations to the etiology. Pain generally shows a procedure that is distal to the dentate, for example, a crevice or thrombosed hemorrhoid. Bleeding is nonspecific and can result from a crevice, polyps, or malignancy, inflammatory gut infection or IBD, internal hemorrhoids, or an ulcerated thrombosis. Hemorrhoid bleeding is normal, however it is uncommon for patients to present with anemia (Kluiber and Wolff, 1994).

Pruritis and "burning" can result from discharges or trouble with cleanliness. It might likewise result from a perpetual injury, for example, a crevice or fistula, condyloma, rectal prolapse, or prolapsing hemorrhoids. A mass might be identified with an abscess, skin tags, neoplasia, or a thrombosed or prolapsed hemorrhoid (Sanchez and Chinn, 2011).

## Assessment of Hemorrhoids

The assessment of hemorrhoids incorporates a total medical history, a physical examination and couple of diagnostic tests.

**Medical History:** A therapeutic history enables the doctor to become familiar with the patient's indications and overall wellbeing. This frequently incorporates inquiries concerning the patient's bowel propensities and diet. The patient may likewise be asked how regularly does he/she exercise, and whether he/she takes any drugs. The patient should mention if any individuals from his/her blood relatives have had cancer or polyps of the colon (Krames Patient Education, 2010).

**Physical Examination:** During a physical test, the patient will be approached to lie on an exam table. He/she will at that point be analyzed for indications of swollen hemorrhoids and different issues. The test takes only a couple of minutes. It is typically not difficult or painful. The physical test essentially comprises of a visual test, a computerized rectal test and an anosopic exam (Krames Patient Education, 2010).

**Diagnostic Tests:** Diagnostic tests help ensure that the manifestations aren't brought about by different issues, for

example, polyps or colorectal malignant growth. These tests incorporate a fecal occult blood test, which checks for shrouded blood in the stool. There might be need of certain tests to investigate the colon. Some tests are: Sigmoidoscopy, Colonoscopy and Barium Enema (Krames Patient Education, 2010).

1. **Sigmoidoscopy:** A sigmoidoscopy is a test used to check the sigmoid colon, which is the lower portion of the colon. This segment of the colon is near the rectum and anus. A sigmoidoscopy may likewise be utilized to take a tissue test or biopsy. Also, it tends to be utilized to expel polyps or hemorrhoids (swollen veins in the rectum and anus). It is additionally a screening test for colon malignancy and rectal cancer. A sigmoidoscopy is performed utilizing a thin, flexible tube called a sigmoidoscope. The tube has a minor light and a camera. The tube is put into the anus and moved gradually through the rectum into the lower portion of colon. The tube is utilized to blow air into the colon, which swells up the colon a bit to improve visibility (Johns Hopkins Medicine, 2019).
2. **Colonoscopy:** A colonoscopy is a test used to recognize changes or variations in the colon and rectum. Amid a colonoscopy, a long, flexible tube (colonoscope) is embedded into the rectum. A small video camera at the tip of the tube enables the specialist to see within the whole colon. If required, polyps or different kinds of irregular tissue can be expelled through the scope amid a colonoscopy. Tissue samples (biopsies) can be taken amid a colonoscopy as well (Mayoclinic, 2019).
3. **Barium Enema:** A barium enema is a radio-graphic test that can recognize changes or variations in the colon. The technique is likewise called a colon X-Ray. An enema is the infusion of a fluid into the rectum through a little tube. For this situation, the fluid contains a metallic substance (barium) that coats the lining of the colon. Typically, an X-Ray delivers a poor picture of delicate tissues, however the barium covering results in a generally clear outline of the colon. Amid a barium enema test, air might be siphoned into the colon. The air swells up the colon and improves the quality of pictures. This is called an air-contrast (two-fold contrast) barium enema. Prior to a barium enema, the specialist will tell the patient to totally empty their colon (Mayoclinic, 2019).

## Management

### Conservative Treatment

This treatment comprises of 3 components: Lifestyle Modification, Oral Medications and Topical Medications.

1. **Lifestyle Modification:** The primary thing of traditional treatment of hemorrhoid is to alter way of life with the goal that the patient can maintain a strategic distance from delayed straining fundamentally by decreasing development of hard stool, which can be accomplished by increasing the intake of dietary fiber and oral liquids. Different elements that may diminish straining incorporate improving anal hygiene, maintaining a strategic distance from pointless straining and drugs, which cause either constipation or diarrhea (Lohsiriwat, 2013; Hall, 2013; Lestar *et al.*, 1989).

2. **Oral Medications:** The job of the medications in the therapy of hemorrhoids is either a defensive treatment for early evaluations where prolapse isn't noteworthy, or as an essential control of the intense bleeding till definitive office procedures or surgery can be done. Micronized Purified Flavonoid Fraction is made out of 90% Diosmin and 10% Hesperidin, and has exhibited viability in the treatment of hemorrhoids. Despite the fact that it has a phlebotonic action, vasculo-protective effects, and antagonism of the biochemical mediators of inflammation, its exact mechanism of activity stays vague. In spite of the fact that flavonoid is the most regularly utilized medication for treatment of hemorrhoid, a meta-examination of 14 randomized clinical trials (RCTs) with respect to the role of flavonoids in the treatment of hemorrhoidal disorder concluded that confinements in methodological quality, heterogeneity and potential production bias bring up issues about the evident helpful impacts of flavonoids in the treatment of hemorrhoidal disorder. Another venotonic drug is Calcium Dobesilate. It improves the reaction of symptomatic intense assaults of first-and second-degree internal hemorrhoids when added to way of life modification (Johanson and Sonnenberg, 1994; Pigot *et al.*, 2005).
3. **Topical Medications:** It has been noticed that well designed investigations have discovered no proof to help the utilization of any of the myriad of OTC topical preparations that contain low-dose local anesthetics, corticosteroids, keratolytics, protectants, or antiseptics (Peery *et al.*, 2015). These drugs are broadly used to diminish symptoms; in any case, their long haul use, especially steroid preparations, might be inconvenient and ought to be discouraged.

### Office Procedures

As per ASCRS Guidelines for Management of Hemorrhoids (2010), there is a strong proposal dependent on moderate-quality proof 1B that early grades including grade I, II and even III that don't react to conservative treatment can be managed with office procedures, which plan to diminish blood flow to the hemorrhoid, decrease the redundant tissue and fix the hemorrhoid to the underlying tissue to lessen prolapse (ASCRS, 2010; Margetis, 2019). The available office procedures are mentioned below.

#### Rubber Band Ligation (Michigan Medicine)

Rubber band ligation is a method wherein the hemorrhoid is tied off at its base with elastic bands, removing the blood flow to the hemorrhoid. This treatment is just for internal hemorrhoids. To do this strategy, a specialist embeds a survey instrument (anoscope) into the anus. The hemorrhoid is picked up with an instrument, and a gadget puts an elastic band around the base of the hemorrhoid. The hemorrhoid at that point shrinks and dies and, in about seven days, falls off. A scar will form instead of the hemorrhoid, holding close-by veins so they don't swell into the anal canal. The patient is asked whether the elastic bands feel excessively tight. In the event that the bands are very agonizing, a medication might be infused into the clubbed hemorrhoids to numb them. After the process, the patient may feel torment and have an impression of fullness in the lower abdomen. Or then again the patient may feel as though he/she needs a defecation. Treatment is constrained to 1 to 2

hemorrhoids at any given moment whenever done in the specialist's office. A few hemorrhoids might be treated at one time if the individual has general anesthesia. Additional areas might be treated at 4-to 6-week interims.

Individuals react contrastingly to this method. Some can come back to standard activities (yet keep away from difficult work) very quickly. Others may require 2 to 3 days of bed rest.

- Pain is likely for 24 to 48 hours after rubber band ligation. The individual may utilize acetaminophen (for instance, Tylenol) and sit in a shallow tub of warm water (sitz bath) for 15 minutes at an opportunity to soothe uneasiness.
- To lessen the danger of bleeding, aspirin ought to be kept away from and other NSAIDs for 4 to 5 days both after the procedure.
- Bleeding may happen 7 to 10 days after medical procedure, when the hemorrhoid falls off. Bleeding is generally slight and stops by itself.

Specialists prescribe that the patient should take stool softeners containing fiber and drink more liquids for smooth defecations. Straining amid defecation can make hemorrhoids return.

Rubber band ligation is the most broadly utilized treatment for internal hemorrhoids. In the event that the patient still have presentation after three or four medications, surgical procedure might be considered. Rubber band ligation can't be utilized if there isn't sufficient tissue to maneuver into the banding gadget. This method is never suitable for fourth-degree hemorrhoids. Rubber band ligation works for around 8 out of 10 individuals. Individuals who have this treatment are less inclined to require another treatment contrasted with individuals who have coagulation treatments. Around 1 out of 10 individuals may require surgical procedure.

Side effects related with RBL are uncommon, however include; severe torment that does not react to the techniques for relief from pain utilized after this process. The bands might be tight near the zone in the anal canal that contains pain sensors. Bleeding and infection due to tightness of the band. Inability to urinate (urinary retention).

#### **Infusion Sclerotherapy** (Sakr and Saed, 2014)

Infusion sclerotherapy has been utilized quite a while in the past for treatment of bleeding hemorrhoids. A few materials including Ethanolamine Oleate, 5% Phenol in Almond oil, Sodium Tetradecyl Phosphate, and Sodium Morrhuate have been utilized as sclerosant that pulverizes the hemorrhoid vascularity and actuates inflammation, which ends with fibrosis that fixes the hemorrhoids to the encompassing tissue. After injection sclerotherapy, the patient requires just mild analgesics. Legitimate instruction in regards to the proper eating regimen, bulking agents and stool softeners just as sitz baths ought to be given to the patient. Intricacies of this process incorporate mostly anorectal canker and other uncommon complexities, which might be fatal similar to necrotizing fasciitis, retroperitoneal sepsis, oleogranuloma (with oil-containing solutions), and respiratory allergic reaction.

A few examinations found that these complexities can be diminished with keeping great outcomes by utilizing more physiological agents, for example, hypertonic saline and 50% dextrose (Kaidar *et al.*, 2007; Mann *et al.*, 1988; Adami *et al.*, 1981; Ponsky *et al.*, 1991).

Associative anal infections, for example, fistulas, tumors, anal fissures, and skin tags are a contraindication to treatment with sclerotherapy. Various examinations that compared various treatment modalities for hemorrhoids demonstrated that sclerotherapy is by all accounts a less effective option (MacRae and McLeod, 1995; Sim *et al.*, 1981).

#### **Infrared Coagulation** (Northshore University Health System)

Infrared coagulation (IRC) is a non-surgical outpatient strategy for the treatment of hemorrhoids. IRC includes the utilization of infrared light as a heat source to rapidly coagulate, or clot, vessels providing blood to the hemorrhoids. A little test is utilized to painlessly convey a couple of short bursts of infrared light to the hemorrhoid. The infrared coagulation causes the enlarged hemorrhoidal tissue to recoil and subside.

The doctor may suggest an infrared coagulation strategy if the patient has:

- bleeding hemorrhoids
- prolapsed hemorrhoids (internal hemorrhoids that project outside the anal opening because of excessive pressure, for example, stressing amid defecation)

The doctor may propose the utilization of an over-the-counter enema to wash down the rectum before the patient leaves his/her home for the IRC methodology. No extraordinary dietary confinements are required before the process. Since IRC is performed without sedation, the patient may safely operate a vehicle to and from the procedure.

The patient should plan to arrive 15 minutes preceding his/her appointment. The IRC methodology more often than not takes around 5-10 minutes. For the process, the patient should lie on his/her left side. A few patients feel warmth in the anal/ rectal zone as the infrared light is applied. Numerous individuals feel less uneasiness during the process.

Any vibe of warmth in the anal/rectal zone that the patient encounters amid and after the IRC method ought to reduce within 60 minutes. Very few patients may encounter less inconvenience, enduring from seven days to 10 days after the procedure. There might be minor post-method bleeding or spotting. The patient may come back to his/her routine activities however keep away from hard work for a couple of days following the process. Patients are given discharge directions/ instructions to take home.

#### **Radiofrequency Coagulation** (Gupta, 2002)

The principle of radiosurgery includes utilizing high-frequency radio waves at 4.0 MHz, conveyed at low temperature through radiofrequency microfiber terminals; the radiofrequency utilized is like that of marine-band radios. The tissue, rather than electrode, fills in as the resistance; hence, there is no heating of the radiofrequency microfiber electrode. The intracellular water in the tissue that serves as resistance from the waves vaporizes without creating any heat, hence evading the potential harm that might be brought about by heat, as is frequently experienced in electrosurgery.

The latter phenomenon is known as cellular volatilization (Pearch, 1986). This tissue vaporization additionally results in significant hemostasis without really burning the tissue. Likewise, there is no threat of shock or burn injury to the patient. Most significant is the way that there is controlled and negligible lateral tissue harm on the grounds that an exceptionally high-frequency radio wave (4.0 MHz) is created at low temperatures in this technique (Sebben, 1998).

### **Bipolar Diathermy and Direct Current Electrotherapy**

Bipolar diathermy and direct-current electrotherapy utilizes local heat application to instigate coagulation and fibrosis that leads to hemorrhoidal fixation. The success rates of the two techniques have been accounted for by a few examinations to be comparable to those of infrared coagulation, and to have a moderately low rate of complications (Dennison *et al.*, 1990; Hinton and Morris, 1990).

### **Cryosurgery**

In this strategy, the doctor will initially utilize local anesthesia to numb the region before applying either nitrous oxide or liquid nitrogen with a cryoprobe to solidify internal or external hemorrhoids. The doctor may likewise tie them off (ligate) before solidifying them. The hemorrhoids dwindle and fall off in 2-3 weeks. There will be more pain after this kind of treatment, and there are increased risks, for example, contamination and bleeding. Cryosurgery was once used commonly, yet most doctors currently settle on an alternate treatment because of the numerous potential complications of this procedure (GI Society).

### **Laser Therapy (Penang Adventist Hospital)**

Laser Therapy or Laser Hemorrhoidoplasty (LHP) is a methodology utilized for treatment of advanced hemorrhoids under local, general or spinal anesthesia. The power of the laser is embedded centrally into the hemorrhoidal node.

There is a direct (30%) and progressive shrinkage of the hemorrhoids (a month and a half to conclusive outcome).

The controlled laser energy deposition crushes the nodes from within and preserves the mucosa and structure of sphincter. The homogenous laser discharge from the LHP fiber results in:

- Closure of the arteries entering the hemorrhoidal cushion
- Tissue decrease in the hemorrhoidal node
- Maximum preservation of muscle, anal coating and mucosa
- Restoration of the common anatomical structure

The controlled emission of laser energy which is applied submucosally, causes the hemorrhoidal mass to dwindle. Also fibrotic remaking creates new connective tissue, which guarantees that the mucosa holds fast to the underlying tissue. This anticipates occurrence or reoccurrence of a prolapsed. No outside materials (clamps) should be embedded and unlike different process, LHP isn't related with any danger of stenosis.

Healing is excellent since, in contrast to traditional surgical procedures there are no incisions on stiches.

Access into the hemorrhoid is accomplished by entering through a little perianal port. By this method no injuries are produced in the region of the anoderm or mucosa. Thus the

patient experience less post-operative agony and can come back to normal activities inside a short span of time.

### **Manual Anal Dilatation (Lord's Procedure)**

This method which was portrayed by Lords in 1969 is utilized generally for 2<sup>nd</sup> & 3<sup>rd</sup> grade hemorrhoids. It is aimed to widen the sphincter (anal) so that 4 fingers of each hand can enter and the laxity of the sphincter is maintained by normal utilization of a dilator (Konsten and Baeten, 2000). General anesthesia is required, however the individual can return home that day. The procedure is currently to a great extent abandoned because of the often inconvenience of incontinence, particularly when used in combination with open hemorrhoidectomy (Mortensen *et al.*, 1987; Creve and Hubens, 1979).

### **Harmonic Ultrasonic Scalpel Hemorrhoidectomy**

The harmonic blade (scalpel) utilizes ultrasonic power, which takes into account both dissecting and clotting of the affected tissue at precise point, bringing about reduced lateral thermal damage (Armstrong *et al.*, 2001). In this procedure the temperatures are less in contrast to electro-medical surgery or LASERs (Armstrong *et al.*, 2001). Coaptive coagulation of bleeding vessels is accomplished somewhere in the range of 50°C and 100°C contrasted with burning by electrocautery at 150°C. The blade that is used here combines with proteins & denatures it to frame a clot that seals the bleeding vessels. This method does not required hospitalization and is suggested for 1<sup>st</sup> & 2<sup>nd</sup> grade hemorrhoids. The duration is long and much painful when contrasted with the LigaSure hemorrhoidectomy (Kwok *et al.*, 2005).

### **Atomizing Hemorrhoids**

This is a new technology where the wand (i.e. atomizing wand) is type of current wherein a specific a probe which is electrical extracts at least one or two cell layers at a time, atomizing the tissues to minute particles, that are promptly suctioned away (Atomizing Hemorrhoids, 2010). The hemorrhoidal tissues are broken down into carbon and water particles. The results are like laser hemorrhoidectomy but there is less bleeding and the cost of treatment is also low (Atomizing Hemorrhoids, 2010). This method is basically suggested for grade I, II & III hemorrhoids. No hospitalization is required. This method is in use only in Arizona, USA (Atomizing Hemorrhoids, 2010).

### **Doppler-guided Hemorrhoidal Artery Ligation**

Kazumasa Morinaga in 1995 depicted an additional method by which the hemorrhoidal arteries could be distinguished by means of Doppler technique (Morinaga *et al.*, 1995). The uniquely planned work had a Doppler transducer and a window. The surgeon could identify and ligate the arteries by tying a suture around them through this window (Felice *et al.*, 2005). All the arteries could be ligated using this strategy. In this process hospitalization is not required and the patient can return home as soon as he is conscious. This method is appropriate for I, II and few selected III degree hemorrhoids. Bleeding is almost nil in this procedure. An examination has given positive conclusion on the safety and viability of this method (Felice *et al.*, 2005). Pure external hemorrhoids will not react to this technique.

## Surgical Treatment

Albeit a few examinations concluded the positive results of safety and effectivity of RBL strategy when contrasted with open method in 3<sup>rd</sup> grade hemorrhoids (Syed *et al.*, 2010), it is expressed that surgical treatment is compulsory in patients suffering from grade III & IV disorder (Sardinha and Corman, 2002). The various surgical options are mentioned below.

### Diathermy Hemorrhoidectomy

In this method, the results are achieved at temperatures more than 150°C. Due to this an eschar is formed that helps in sealing the bleeding site. This method results in less bleeding, shorter duration and reduced requirement of analgesia after procedure unlike conventional hemorrhoidectomy (CH). But the level of pain remains same (Armstrong *et al.*, 2002).

### LigaSure and Starion Hemorrhoidectomy

A generator known as the LigaSure vessel-sealing generator is used in this method. This generator is an electrical generator that is responsible for sealing and surgery specifically bipolar (Iyer *et al.*, 2004). It gives exact thermal power and pressure to vessels to accomplish total and changeless combination of the lumen. The other method i.e. Starion thermal welding technique just like the previous method however utilizes an innovation that helps in the welding of the tissue to combine vessels and tissue structures. The temperature should be under 100°C for smooth operation. The activity is done under general or epidural anesthesia. Before making a V-shaped cut at the junction of the hemorrhoid and the peri-anal skin general anesthesia should be given. This incision is trailed by cutting of the hemorrhoidal bundles under sphincter. An investigation exhibited that the Starion hemorrhoidectomy is less painful than LigaSure hemorrhoidectomy, however both the methods have similar advantages of shorter duration and less blood loss (Iyer *et al.*, 2004).

### Semi Closed Hemorrhoidectomy

This method involves the repair of the pectineal line. It was introduced by Reis Neto. In this method the internal hemorrhoid is completely exposed outside; 3 to 4 thick stitches are made radially in the mucosa as well as the submucosa, along the craniocaudal length of the hemorrhoid to be resected. The mucosa and submucosa are cut between the ligations; the outer piece of the skin is excised till the pectineal line with a V-formed incision or a racket cut with an external base. This method is ideal for voluminous and proximally expanded internal hemorrhoids, whose full dissection would cause a high resection of the rectal mucosa (Reis *et al.*, 2005).

### Submucosal Hemorrhoidectomy (Park's Procedure)

This technique was created during the 1950s by Parks, who distributed outcomes and subtleties of the procedure in 1956 (Hiteshkumar *et al.*, 2013). It was intended to lessen pain after the procedure and prevent the stenosis of anus and rectum. It is recommended in 2<sup>nd</sup> to 4<sup>th</sup> grade disorder. A Parks retractor is embedded. With the help of a hemostat a position just below the dentate line is held. 1:400,000 parts of adrenaline in a saline of 30 – 40 ml is infused to open the tissue linings and to lessen bleeding. Scissors are utilized to extract a small portion of anal tissue around the hemostat.

The cut is proceeded cranially for 2.5 cm, making two flaps on every side, which are held with hemostats, and submucosal dissecting is initiated to expel the hemorrhoidal plexus from underlying inner sphincter muscle and overlying mucosa. After this the dissection proceeds to the rectal area. Here the base of the tissue is stitched-ligated and divided. Further the flaps are allowed to recoil or fold back into their position. The need of sutures in this method is for prolapsed hemorrhoid to rebuild the tendons, however it is suggested to suture the mucosal folds together. A similar methodology is completed on other hemorrhoids. This method is considered safe and there are low rates of difficulties and recurrence (Hiteshkumar *et al.*, 2013). The duration is long and is progressively hard to learn. An ongoing report reasoned that the changed lift-up submucosal hemorrhoidectomy is a simpler operative technique contrasted with the method initially created by Parks (Shanmugam *et al.*, 2005).

### Farag's Procedure (Farag, 1978)

There are a few techniques to tie up hemorrhoidal artery without Doppler, like using sutures is a basic strategy (presented by Farag in 1978) in which the use of 3 sutures in prolapsed hemorrhoid compromise the blood flow to the hemorrhoid. The first suture blocks the rectal arteries when it is passed through the proximal end of the internal hemorrhoid. The second suture interferes between outer and inner plexus when it is passed through the distal end of the internal hemorrhoid. The last suture is between the first 2 sutures. In any case, this procedure and its adjustments, were not generally acknowledged on account of the underlying agonizing congestion that came about because of intrusion of the blood flow to the hemorrhoidal cushions, however it was trailed by continuous shrinkage of the prolapsed piles.

### Anopexy

It is one of the basic method to treat advanced hemorrhoids. The outcomes are controlled bleeding, the prolapse of hemorrhoid decreases and healing the hemorrhoidal cushions under the tissues. It depends on 2 facts (1) location of the hemorrhoidal vessels so that a suture can be put at the base of the hemorrhoidal cushion essentially diminishes the blood flow to the hemorrhoidal plexus; and (2) development of the hemorrhoids on damage of tissue that support the cushions (sliding anal canal lining theory). This can be corrected by repairing of the hemorrhoidal cushions to the underlying inside sphincter (Awojobi, 1983).

A few names have been coined to this methodology including "pile suture", "suture ligation", "obliterative suture technique", "ligation and anopexy", and "ligation and mucopexy" (Farag, 1978; Awojobi, 1983; Hussein, 2001; Gupta and Kalaskar, 2008).

### Stapled Hemorrhoidectomy

This technique is otherwise called circumferential mucosectomy or 'procedure for prolapse and hemorrhoids' (PPH). Longo in the year 1998 portrayed this method for treating 2<sup>nd</sup> to 4<sup>th</sup> grade disorder (Clay *et al.*, 1986). According to him the hemorrhoidal cushion could be lifted up by the dentate line to the anal canal by stapled resection. This could be achieved by stapling the total circular strip of mucosa over the dentate line (Clay *et al.*, 1986). In PPH, the prolapsed tissue is maneuvered into a round stapler that enables the excessive tissue to be expelled while the remaining hemorrhoidal tissue is stapled. In the anal canal a

circular anal dilator is inserted. On removing the dilator the prolapsed mucous layer falls into the lumen. Now through the dilator a purse-string suture anoscope is then inserted, so as to make a suture around the whole anal canal perimeter. The circular stapler is opened to its most extreme position. Its head is acquainted and situated proximal with the purse-string suture, which is then tied with an end hitch. The whole packaging of the stapler is then pushed into the anal canal, tightened & fired to staple the prolapse. A row of titanium staples through the tissue is discharged by firing the stapler. A circular blade extracts the excess tissue, accordingly expelling a circumferential segment of mucosa from the upper anal canal. After analyzing, if any bleeding is present, arrangements are made to stop or absorb the bleeding. There should be a gap of at least 3 to 3.5 cm between the staple lines to prevent post-operative rectal stenosis. Patients experience less agony and accomplish a snappier come back to work contrasted with regular techniques; and bleeding is less (Clay *et al.*, 1986).

### Clamp and Cautery Hemorrhoidectomy

This strategy is currently out of date however has the preferred position in not having any type of dissection of tissue linings. The hemorrhoids are held between the insulated blades of Smith's pile clamp. Most of the hemorrhoidal tissue is then removed, leaving just a small mass, which is scorched using cautery to inhibit bleeding (Labrid, 1994). The cautery is generally heated over fire, which is only occasionally accessible in a modern OT nowadays. The electric burning or diathermy blades are inadmissible substitutes since they are ineffectual in inhibiting hemorrhage and in light of the fact that the coagulating current may enter tissues too profoundly. The procedure is done for 2<sup>nd</sup> to 4<sup>th</sup> grade hemorrhoids and it is done under general anesthesia.

### Open Hemorrhoidectomy (Milligan – Morgan Method)

This is the most ordinarily utilized procedure and is generally viewed as the best surgical technique for treating hemorrhoids (Labrid, 1995). An investigation demonstrated that open hemorrhoidectomy was the prevalent surgical technique for treating hemorrhoids (Struckmann and Nicoladies, 1994). An examination additionally inferred that open hemorrhoidectomy was safe, basic and financially savvy, with postoperative agony, intense urine retention and bleeding remaining the major complications (Chong and Bartolo, 2008; Hain, 2011).

It is the method of choice for 3<sup>rd</sup> & 4<sup>th</sup> grade hemorrhoids.

In 1937 this method was portrayed by Dr. Milligan & Dr. Morgan in the UK, for treating 2<sup>nd</sup> to 4<sup>th</sup> grade disorder (La Torre and Nicolai, 2004). A V patterned cut is made at the base of the hemorrhoid that is followed till the submucosal space until the complete hemorrhoidal tissue is dissected from its bed. The dissection is conveyed cranially to the pedicle, which is ligated with strong catgut and the distal part extracted. The remaining tissues are also treated similarly, leaving a skin bridge in the middle to avoid stenosis. The incision is left open and to stop bleeding (hemostatic bandage) is kept in the anal canal. The method is done under general or epidural anesthesia. Pain and urine retention are common.

### Closed Hemorrhoidectomy (Ferguson's Method)

In 1952 Dr. Ferguson and Dr. Heaton created this method in the US. It was an alteration of Milligan-Morgan method (Misra, 2005). This method is used in the same indications as Milligan-Morgan technique. Here the cuts are absolutely or partially covered with absorbable running suture, following surgical extraction of the hemorrhoidal tissues. The Ferguson technique does not have advantage towards healing due to the high rate of suture breakage at bowel movement (Misra, 2005).

### Whitehead's Circumferential Hemorrhoidectomy

In 1882, Dr. Walter Whitehead first introduced this strategy, otherwise called total or circumferential hemorrhoidectomy (Scarpa *et al.*, 1988). After beginning achievement, the system was later surrendered because of the high intricacy rates experienced: hemorrhage, anal stenosis, and ectropion (Whitehead's deformation). The method involves circumferential extraction of the hemorrhoidal tissues, hemorrhoid-bearing rectal mucosa only proximal to the dentate line. Cuts are made by specially designed scissors only proximal to the dentate line and proceeded with this way around the anal canal in stages. Clamps are utilized to lift the cut edge of the hemorrhoid rectal - bearing mucosa and mucosal prolapse. The hemorrhoidal masses are then suture-ligated and extracted, trailed by closure of the cuts by suture. For the suture to go through the endoderm till the neo dentate line, a retractor is utilized. A bandage or a sponge that can stop bleeding is kept in the anal canal. If the hemorrhoids are circumferential, the process reversed and is done under general anesthesia. Recent studies revealed that Whitehead's hemorrhoidectomy still has a place in selected cases of circumferential hemorrhoids (Scarpa *et al.*, 1988).

### Conclusion

Hemorrhoids are one of the most commonly occurring anorectal disorders that compromises the quality of life of an individual. Although there some drugs available to treat the symptoms and there are some office procedures for treating Grade I & II disorders. But when these measures fail to treat the condition or in patients with higher grade disorder surgical interventions should be considered. In spite of various options available for the treatment of Hemorrhoids, many individuals are unaware about this. This leads to a drastic decrease in the Quality of Life of patients suffering from this disorder. Currently there are various methods available for the treatment of this disorder. Some are traditional and some are novel. A proper diagnosis will help in selecting the proper treatment for the patient.

### References

- Adami, B.; Eckardt, V.F.; Suermann, R.B.; Karbach, U. and Ewe, K. (1981). Bacteremia after proctoscopy and hemorrhoidal injection sclerotherapy. *Dis Colon Rectum*, 24: 373-374.
- Agbo, S.P. (2011). Surgical Management of Hemorrhoids. *J Surg Tech Case Rep.*, 3(2):68-75.
- Agrawal, S. and Chopra, S. (2016). Comparative Study between Conventional Hemorrhoidectomy versus Stapled Hemorrhoidopexy at Ja Group of Hospitals Gwalior. *IOSR J Dental Med Sci.*, 15(12):69-94.
- Aigner, F.; Bodner, G.; Gruber, H.; Conrad, F.; Fritsch, H.; Margreiter, R. and Bonatti, H. (2006). The vascular

- nature of hemorrhoids. *J Gastrointest Surg.*, 10: 1044-1050.
- Aigner, F.; Gruber, H.; Conrad, F.; Eder, J.; Wedel, T.; Zelger, B.; Engelhardt, V.; Lametschwandtner, A.; Wienert, V.; Böhler, U.; Margreiter, R. and Fritsch, H. (2009). Revised morphology and hemodynamics of the anorectal vascular plexus: impact on the course of hemorrhoidal disease. *Int. J Colorectal Dis.*, 24: 105-113.
- American Society of Colon and Rectal Surgeons. Management of Hemorrhoids – Practice Parameters for the Management of Hemorrhoids. ASCRS; 2010.
- Armstrong, D.N.; Ambrose, W.L.; Schertzer, M.E. and Orangio, G.R. (2001). Harmonic scalpel Vs electrocautery hemorrhoidectomy: A prospective evaluation. *Dis Colon Rectum.*, 44: 558–64.
- Armstrong, D.N.; Frankum, C.; Schertzer, M.E.; Ambroze, W.L. and Orangio, G.R. (2002). Harmonic scalpel hemorrhoidectomy: five hundred consecutive cases. *Dis Colon Rectum*, 45: 354-359.
- Atomizing Hemorrhoids. [Last accessed on 2010 July 10]. Available From: [www.proctology.us/atomizing.php](http://www.proctology.us/atomizing.php).
- Awojobi, O.A. (1983). Modified pile suture in the outpatient treatment of hemorrhoids. A preliminary report. *Dis Colon Rectum*, 26: 95-97.
- Chong, P.S. and Bartolo, D.C. (2008). Hemorrhoids and fissure in ano. *Gastroenterol Clin North Am.*, 37: 627-644.
- Cintron, J. and Abacarian, H. (2007). Benign anorectal hemorrhoids. In: Wolff BG, Fleshman JW. *The ASCRS of Colon and Rectal Surgery*. New York, NY: Springer-Verlag, 156–177.
- Clay, L.D.; White, J.J.; Davidson, J.T. and Chandler, J.J. (1986). Early recognition and successful management of pelvic cellulitis following hemorrhoidal banding. *Dis Colon Rectum*, 29: 579-581.
- Creve, U. and Hubens, A. (1979). The effect of Lord's procedure on anal pressure. *Dis Colon Rectum*, 22: 483–5.
- Dennison, A.; Whiston, R.J.; Rooney, S.; Chadderton, R.D.; Wherry, D.C. and Morris, D.L. (1990). A randomized comparison of infrared photocoagulation with bipolar diathermy for the outpatient treatment of hemorrhoids. *Dis Colon Rectum.*, 33: 32-34.
- Deutsch, A.A.; Moshkovitz, M.; Nudelman, I.; Dinari, G. and Reiss, R. (1987). Anal pressure measurements in the study of hemorrhoid etiology and their relation to treatment. *Dis Colon Rectum*, 30: 855-857.
- Ellesmore, S. and Windsor, A.C. (2002). Surgical history of hemorrhoids. In: Charles MV, (editor): *Surgical treatment of hemorrhoids*. Springer: London; 1-4.
- Farag, A.E. (1978). Pile suture: a new technique for the treatment of hemorrhoids. *Br J Surg*, 65: 293-295.
- Felice, G.; Privitera, A.; Ellul, E. and Klaumann, M. (2005). Doppler- Guided Hemorrhoidal Artery ligation: An alternative to Haemorrhoidectomy. *Dis Colon Rectum*, 48: 2090–3.
- Fox, A.; Tietze, P.H. and Ramakrishnan, K. (2014). Anorectal conditions: hemorrhoids. *FP Essent*, 419: 11-19.
- Ganz, R.A. (2013). The evaluation and treatment of hemorrhoids: a guide for the gastroenterologist. *Clin Gastroenterol Hepatol.*; 6: 593-603.
- GI Society. Hemorrhoids. Canadian Society of Intestinal Research.
- Gupta, P.J. and Kalaskar, S. (2008). Ligation and mucopexy for prolapsing hemorrhoids--a ten year experience. *Ann Surg Innov Res.*, 2: 5.
- Gupta, P.J. Novel Technique: Radiofrequency Coagulation -- A Treatment Alternative for Early-Stage Hemorrhoids. *Medscape General Medicine [Internet]*. 2002 [cited on 2019 Apr 01]; 4(3).
- Hain, J.M. (2011). Medical treatment of hemorrhoids using flavonoids. *Pract Gastroenterol*, (March Supp): 1-5.
- Hall, J.F. (2013). Modern management of hemorrhoidal disease. *Gastroenterol Clin North Am.*, 42: 759-772.
- Han, W.; Wang, Z.J.; Zhao, B.; Yang, X.Q.; Wang, D.; Wang, J.P.; Tang, X.Y.; Zhao, F. and Hung, Y.T. (2005). [Pathologic change of elastic fibers with difference of microvessel density and expression of angiogenesis-related proteins in internal hemorrhoid tissues]. *Zhonghuaweichang Waike Zazhi*, 8: 56-59.
- Hinton, C.P. and Morris, D.L. (1990). A randomized trial comparing direct current therapy and bipolar diathermy in the outpatient treatment of third-degree hemorrhoids. *Dis Colon Rectum*, 33: 931-932.
- Hiteshkumar, D.; Amul, N.; Asutosh, P.C. and Rachit, M. (2013). Calcium Dobesilatein symptomatic treatment of hemorrhoidal disease: an interventional study. *National J Med Res.*, 3: 42-44.
- Holley, C.J. (1946). History of hemorrhoidal surgery. *South Med J.*, 39: 536-541.
- Hulme-Moir, M. and Bartolo, D.C. (2001). Hemorrhoids. *Gastroenterol Clin North Am.*, 30: 183-197.
- Hussein, A.M. (2001). Ligation-anopexy for treatment of advanced hemorrhoidal disease. *Dis Colon Rectum*, 44: 1887-1890.
- Hyung Kyu Yng (2014). The pathophysiology of hemorrhoids. In: Hyung Kyu Yng (editor): *Hemorrhoids*. Springer-Verlag, Berlin Heidelberg, 15-24.
- Iyer, V.S.; Shrier, I. and Gordon, P.H. (2004). Long-term outcome of rubber band ligation for symptomatic primary and recurrent internal hemorrhoids. *Dis Colon Rectum*, 47: 1364-1370.
- Jacobs, D. (2014). Clinical practice. Hemorrhoids. *N Engl J Med.*, 371: 944-951.
- Johannsson, H.O.; Graf, W. and Pählman, L. (2005). Bowel habits in hemorrhoid patients and normal subjects. *Am J Gastroenterol*, 100: 401-406.
- Johanson, J.F. and Sonnenberg, A. (1994). Constipation is not a risk factor for hemorrhoids: a case-control study of potential etiological agents. *Am J Gastroenterol*, 89: 1981-1986.
- Johns Hopkins Medicine [Internet]. Baltimore: Johns Hopkins Medicine. [cited on 2019 Apr 20]. Available from: <https://www.hopkinsmedicine.org/health/treatment-tests-and-therapies/sigmoidoscopy>.
- Jose Marcio Neves Jorge, Angelita Habr-Gama. Anatomy and embryology of the colon, rectum, and anus. In Beck D, Roberts P, Saclarides T, Senagore A, Stamos M, Wexne S (editors): *ASCRS Manual of Colon and Rectal Surgery*, 2nd edition. Springer: New York Dordrecht Heidelberg London; 2011, pp.1-22.



- Kaidar-Person, O.; Person, B. and Wexner, S.D. (2007). Hemorrhoidal disease: A comprehensive review. *J Am Coll Surg.*, 204: 102-117.
- Kann, B.R. and Whitlow, C.B. (2004). Hemorrhoids: diagnosis and management. *Tech Gastrointest Endosc.*, 6: 6-11.
- Kluiber, R.M. and Wolff, B.G. (1994). Evaluation of anemia caused by hemorrhoidal bleeding. *Dis Colon Rectum.*, 37(10): 1006–1007.
- Konsten, J. and Baeten, C.G. (2000). Hemorrhoidectomy Vs Lord's method: 17-year follow-up of a prospective randomized trial. *Dis Colon Rectum.*, 43: 503–6.
- Krames Patient Education. *Treating Hemorrhoids.* The StayWell Company; 2010.
- Kwok, S.Y.; Chung, C.C.; Tsui, K.K. and Li, M.K. (2005). Double blind randomized trial comparing LigaSure and Harmonic Scalpel hemorrhoidectomy. *Dis Colon Rectum.*, 48: 344–8.
- La Torre, F. and Nicolai, A.P. (2004). Clinical use of micronized purified flavonoid fraction for treatment of symptoms after hemorrhoidectomy: results of a randomized, controlled, clinical trial. *Dis Colon Rectum.*, 47: 704-710.
- Labrid, C. (1995). A lymphatic function of Daflon 500 mg. *Int Angiol.*, 14: 36-38.
- Labrid, C. (1994). Pharmacologic properties of Daflon 500 mg. *Angiology.*, 45: 524-530.
- Lestar, B.; Penninckx, F. and Kerremans, R. (1989). The composition of anal basal pressure. An in vivo and in vitro study in man. *Int J Colorectal Dis.*, 4: 118-122.
- Lohsiriwat, V. (2013). Approach to hemorrhoids. *Curr Gastroenterol Rep.*, 15: 332.
- MacRae, H.M. and McLeod, R.S. (1995). Comparison of hemorrhoidal treatment modalities. A meta-analysis. *Dis Colon Rectum.*, 38: 687-694.
- Mann, C.V.; Motson, R. and Clifton, M. (1988). The immediate response to injection therapy for first-degree hemorrhoids. *J R Soc Med.*, 81: 146-148.
- Margetis, N. (2019). Pathophysiology of Internal Hemorrhoids. *Ann Gastroenterol.*
- Mayoclinic [Internet]. [Place Unknown]. Mayoclinic. [cited on 2019 May 01].
- Michigan Medicine. Hemorrhoids. University of Michigan.
- Misra, M.C. (2005). Drug treatment of hemorrhoids. *Drugs.*, 65: 1481-1491.
- Morinaga, K.; Hasuda, K. and Ikeda, T.A. (1995). Novel therapy for hemorrhoids: Ligation of the hemorrhoidal artery with a newly devised instrument (Moricorn) in conjunction with a Doppler flow meter. *Am J Gastroenterol.*, 90: 610–3.
- Mortensen, P.E.; Olsen, J.; Pedersen, L.K. and Christiansen, J. (1987). A randomized study on hemorrhoidectomy combined with anal dilatation. *Dis Colon Rectum.*, 30: 755–7.
- Mott, T.; Latimer, K. and Edwards, C. (2018). Hemorrhoids: diagnosis and treatment options. *Am Fam Physician.*, 97: 172-179.
- Nivatvongs S-. Hemorrhoids (2007). In Gordon P, Nivatvongs S (editors): Principles and practice of surgery for the colon, rectum and anus, 3rd edition. Informa healthcare, New York London, 143-166.
- Northshore University Health System. Infrared Coagulation. Northshore University.
- Pearch, J.A. (1986). *Electrosurgery.* New York: John Wiley and Sons.
- Peery, A.F.; Sandler, R.S. and Galanko, J.A. (2015). Risk factors for hemorrhoids on screening colonoscopy. *PLoS One.*, 10:e0139100.
- Penang Adventist Hospital. Hemorrhoid Surgery/ Laser Hemorrhoidoplasty (LHP). Penang Adventist Hospital.
- Pigot, F.; Siproudhis, L. and Allaert, F.A. (2005). Risk factors associated with hemorrhoidal symptoms in specialized consultation. *Gastroenterol Clin Biol.*, 29: 1270-1274.
- Ponsky, J.L.; Mellinger, J.D. and Simon, I.B. (1991). Endoscopic retrograde hemorrhoidal sclerotherapy using 23.4% saline: a preliminary report. *Gastrointest Endosc.*, 37: 155-158.
- Reis Neto, J.A.; Reis, J.A.; Kagohara, O. and Simões Neto, J. (2005). Semi-open hemorrhoidectomy. *Tech Coloproctol.*, 9: 159-161.
- Riss, S.; Weiser, F.A. and Schwameis, K. (2012). The prevalence of hemorrhoids in adults. *Int J Colorectal Dis.*, 27: 215-220.
- Sakakibara, R.; Tsunoyama, K. and Hosoi, H. (2010). Influence of body position on defecation in humans. *Low Urin Tract Symptoms.*, 2: 16-21.
- Sakr, M. and Saed, K. (2014). Recent Advances in the Management of Hemorrhoids. *World Jr Surg Proc.*, 4(3): 55–65.
- Salvati, E.P. (1999). Nonoperative management of hemorrhoids: evolution of the office management of hemorrhoids. *Dis Colon Rectum.*, 42: 989-993.
- Sanchez, C. and Chinn, B.T. (2011). Hemorrhoids. *Clinics of Colon and Rectal Surgery.*, 24(1): 5-11.
- Sandler, R.S. and Peery, A.F. (2019). Rethinking what we know about hemorrhoids. *Clin Gastroenterol Hepatol.*, 17: 8-15.
- Sardinha, T.C. and Corman, M.L. (2002). Hemorrhoids. *Surg Clin North Am.*, 82: 1153-1167.
- Scarpa, F.J.; Hillis, W. and Sabetta, J.R. (1988). Pelvic cellulitis: a life-threatening complication of hemorrhoidal banding. *Surgery.*, 103: 383-385.
- Schubert, M.C.; Sridhar, S.; Schade, R.R. and Wexner, S.D. (2009). What every gastroenterologist needs to know about common anorectal disorders. *World J Gastroenterol.*, 15: 3201-3209.
- Sebben, J. (1998). Electrosurgery: High frequency modulation. *J Dermatol Surg Oncol.*, 14: 367-371.
- Senagore, A.J. (2002). Surgical management of hemorrhoids. *J Gastrointest Surg.*, 6: 295-298.
- Shanmugam, V.; Thaha, M.A.; Rabindranath, K.S.; Campbell, K.L.; Steele, R.J. and Loudon, M.A. (2005). Systematic review of randomized trials comparing rubber band ligation with excisional hemorrhoidectomy. *Br J Surg.*, 92: 1481-1487.
- Sim, A.J.; Murie, J.A. and Mackenzie, I. (1981). Comparison of rubber band ligation and sclerosant injection for first and second degree hemorrhoids-- a prospective clinical trial. *Acta Chir Scand.*, 147: 717-720.
- Smith, L.E. (2004). Hemorrhoids. In: Fazio V, ed. *Current Therapy in Colon and Rectal Surgery.* St. Louis, MO: Mosby, 11–18.
- Struckmann, J.R. and Nicolaidis, A.N. (1994). Flavonoids. A review of the pharmacology and therapeutic efficacy of Daflon 500 mg in patients with chronic venous

- insufficiency and related disorders. *Angiology*, 45: 419-428.
- Syed, A.A.; Agha, T.M.; Mohammad, J.; Javeria, I.; Akmal, J.S. and Abdul, G. (2010). Outcome of the rubber band ligation with Milligan-Morgan hemorrhoidectomy. *J Ayub Med Coll Abbottabad*, 22: 56-60.
- Thomson, W.H. (1975). The nature of hemorrhoids. *Br J Surg.*, 62: 542-552.
- Yoon, S.O.; Park, S.J.; Yun, C.H. and Chung, A.S. (2003). Roles of matrix metalloproteinases in tumor metastasis and angiogenesis. *J Biochem Mol Biol.*, 36: 128-137.

